



Multiple Schwannomas of ulnar nerve: case report

Schwannoma multiplo del nervo ulnare: caso clinico

Maria Panzarella¹, Giorgio Merlino¹, Natascia Cinatti², Marco Borsetti¹

¹ Division of Plastic Surgery, Hand Surgery and Microsurgery, Surgical Department of ASL Città di Torino, Maria Vittoria Hospital, Turin, Italy;

² Department of Pathology, San Giovanni Bosco Hospital, Turin, Italy

Riassunto

Introduzione. Lo Schwannoma è il tumore benigno più frequente del sistema nervoso periferico.

Case report. Un paziente maschio di 23 anni con una neoformazione sottocutanea a livello della eminenza ipotenar della mano dx giunge alla nostra attenzione. Indagini di approfondimento ponevano diagnosi di sospetto Schwannoma del nervo ulnare.

Risultati. La diagnosi è stata confermata intraoperatoriamente e istologicamente; il decorso postoperatorio è stato privo di complicanze. A distanza di sei mesi non sono stati riscontrati segni di recidiva.

Discussione. Lo schwannoma è il più frequente tumore benigno del sistema nervoso periferico e può essere associato o meno a compromissione neurologica. Solitamente si presenta come nodulo singolo, raramente con aspetto multinodulare. Il rischio di degenerazione maligna è molto basso.

Conclusioni. Lo Schwannoma multiplo dell'arto superiore e del nervo ulnare è molto raro: una accurata diagnosi e competenze microchirurgiche sono necessarie per il corretto trattamento di tale patologia.

Parole chiave: Schwannoma multiplo, nervo ulnare, tumori del sistema nervoso periferico, schwannoma dell'arto superiore, neurofibroma

Summary

Introduction. Schwannomas are the most common benign tumors of peripheral nerves.

Case report. A 23-year-old male patient with a mass in the hypothenar region of his right hand came to our hospital; radiological examination suggested of schwannoma of ulnar nerve.

Results. Intraoperative evaluation and histological exam confirmed suspected diagnosis. The postoperative period was uneventful and at six months follow-up no tumor recurrence was detected.

Discussion. Schwannoma is most common benign tumor of peripheral nerve sheath with or without associated neurological impairment. They are usually found as a solitary lesion but rarely they could have a multinodular presentation. Malignant transformation is very uncommon.

Conclusions. Multiple schwannomas of upper limb and ulnar nerve is very rare: a proper diagnosis and microsurgical skills are mandatory to well treat this pathological condition.

Key words: Multiple schwannomas, ulnar nerve, peripheral nerve sheath tumors, schwannoma of upper extremity, neurofibroma

Corrispondenza:

Maria Panzarella
maria.pnz@gmail.com

Conflitto di interessi

Gli Autori dichiarano di non avere alcun conflitto di interesse con l'argomento trattato nell'articolo.

Come citare questo articolo: Panzarella M, Merlino G, Cinatti N, et al. Multiple Schwannomas of ulnar nerve: case report. Rivista Italiana di Chirurgia della Mano 2024;61:44-49. <https://doi.org/10.53239/2784-9651-2024-8>

© Copyright by Pacini Editore Srl



OPEN ACCESS

L'articolo è OPEN ACCESS e divulgato sulla base della licenza CCBY-NC-ND (Creative Commons Attribuzione - Non commerciale - Non opere derivate 4.0 Internazionale). L'articolo può essere usato indicando la menzione di paternità adeguata e la licenza; solo a scopi non commerciali; solo in originale. Per ulteriori informazioni: <https://creativecommons.org/licenses/by-nc-nd/4.0/deed.it>

Introduction

Schwannomas are the most common tumors of peripheral nerves; they are benign lesions originating from Schwann cells along the course of the nerve; they are usually found as a solitary lesion but rarely they could have a multinodular presentation related or not to neurofibromatosis type 2. They usually appear as a subcutaneous mass that sometimes results painful with positive Tinel's sign and it could be associated with paraesthesia or other neurological impairment; they are characterized by slow growth and a well-defined capsule that allow tumor enucleation^{2,3}.

Medical history, physical examination, radiologic evaluation and microsurgical skills are fundamental to correctly diagnose and treat this pathology⁴.

The aim of this paper is to present a case of multiple schwannomas of right ulnar nerve; the location and multifocal aspect of this tumor lead to the peculiar presentation.

Upper limb and ulnar nerve localisation is rare and only very few cases are reported in literature.

Case report

A 23-year-old male patient came to our hospital complaining of pain on his right hand in the hypothenar region in which he presented a swelling area; this mass was present since two years with a history of progressive and slowly growth; he referred pain caused by compression but not sensibility impairment; there was no history of any significant trauma and he had not any relevant past medical problem. The patient did not have symptoms suggestive of neurofibromatosis, neither did he have a first degree relative with neurofibromatosis. He is a mechanical engineer exposed to repeated micro traumas due to vibrations of industrial machinery. The patient was studied by an ultrasound evaluation and a magnetic resonance exam to assess mass location and signal pattern. These exams showed the presence of multinodular formations along the course of ulnare nerve from Guyon's canal to mid-palm; they were suspected for neurinoma/neurofibromas. These formations were about 2 cm (Fig. 1). On physical examination only major mass was visible and palpable; it was fixed and painful at compression; Tinel's sign was lightly positive with a tingling sensation after percussion; not evidence of muscle weakness or signs of atrophy of intrinsic hand musculature have been detected; Froment's sign was negative; range of motion was complete and two-point-discrimination test was normal.

After collegial discussion of the case, surgery was scheduled: surgical exploration and tumor enucleation was the plan, but patient was informed about the need of neurorrhaphy or nerve graft in case of nerve resection.

Surgical procedure was carried out under general anaesthe-

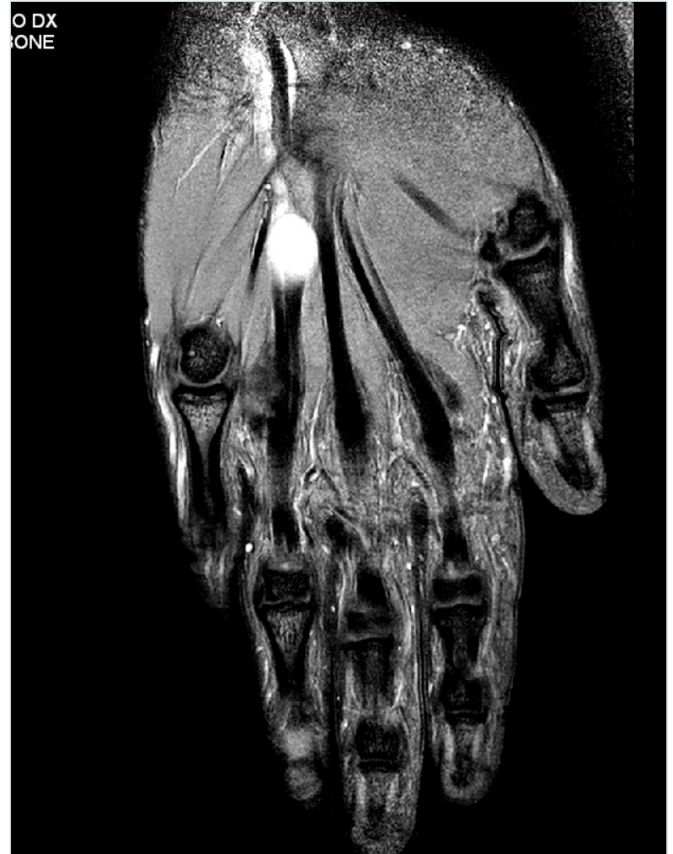

Figure 1. Contrast-enhanced preoperative magnetic resonance image: multinodular formation along the course of ulnar nerve.

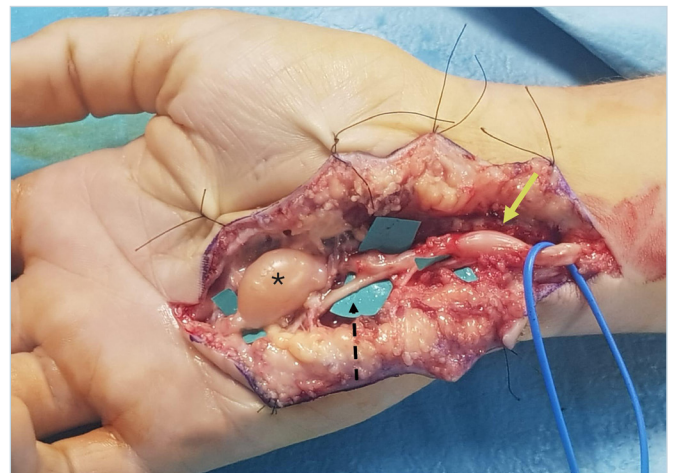


Figure 2. Intraoperative findings: the ulnar nerve was dissected from the wrist to its distal ramifications; the greatest mass arose from superficial sensory branch (black asterisk); the smaller lesion was inside Guyon's canal and involved ulnar nerve before its bifurcation (yellow arrow). The deep branch after bifurcation was normal (black dotted arrow).

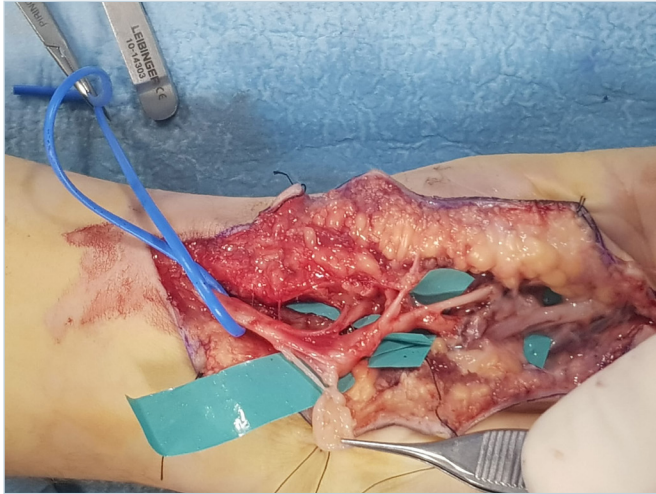


Figure 3. Intraoperative view after tumors removal without injury nerve bundles.

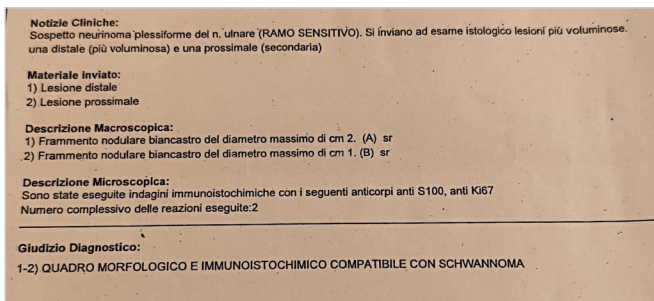


Figure 4. Microscopic and histological diagnosis

sia and loupes magnification; a longitudinal Z-plasty incision was made on Guyon’s canal to identify healthy ulnar nerve that was followed and carefully dissected from distal third of the arm to all its distal palmar ramifications with consequent multinodular formation exposition: the greatest mass arose from superficial sensory branch of ulnar nerve at the exit of Guyon’s canal followed by three little formations in digital branches to IV and V finger; the smaller lesion was inside Guyon’s canal and involved ulnar nerve before its bifurcation. The deep branch after bifurcation was normal (Fig. 2). After carefully dissection and neurolysis, the neural sheath of bigger masses was incised and tumors removed without injury nerve bundles; no nerve section neither nerve graft needed. We left in their place smallest nodularity to avoid nerve injury as they were asymptomatic (Fig. 3). The patient was discharged the day after surgery with a soft bandage. Macroscopic examination showed yellowish soft nodular for-

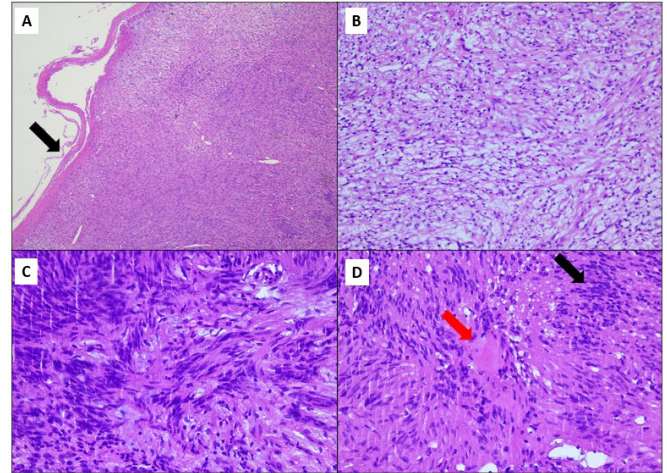


Figure 5. Histologic section showing a thin capsule consisting of fibrocollagenous material (image A, black arrow H&E 2,5x); the cellular component shows a zonal distribution of hypocellular areas with loose textured myxoid stroma, defined as «Antoni B» (image B, 10x) and hypercellular areas with compact elongated cells with cytologically bland spindle-cell nuclei with ample eosinophilic cytoplasm and poorly defined cell membranes, defined as «Antoni A». Note the transition between the two areas from Antoni A (upper left) to Antoni B (bottom right) (image C, H&E, 20x). The pathognomonic feature is the Verocay body, which consists of a stacked arrangement of two parallel rows of fusiform palisading nuclei (black arrow) separated by an anuclear zone (red arrow) (image D, H&E, 20x)

mations with diameter between 1 and 2.5 cm. S-100 protein and anti Ki67 immunohistochemical reactions were positive: microscopic and histological examination were in accord with diagnosis of multiple schwannomas. (Figs. 4, 5) Two weeks after surgery the skin sutures were removed; at that time patient complained numbness on the ulnar side of fourth finger and on the radial side of little finger; there was no ulnar motor impairment and scar was normotrophic (Fig. 6). Sensibility recovery it has been improving with time and six months after the surgery full ulnar motor and sensory function was restored. No Tinel sign on the palm neither pain have been observed. Residual mild paraesthesia on the ulnar side of fourth finger was detected but without any impact on daily activity. At six months follow-up, magnetic resonance showed no tumor recurrence and size reduction of little nodules left in place (Fig. 7). The patient did not require any physical therapy and he was allowed to come back to work.

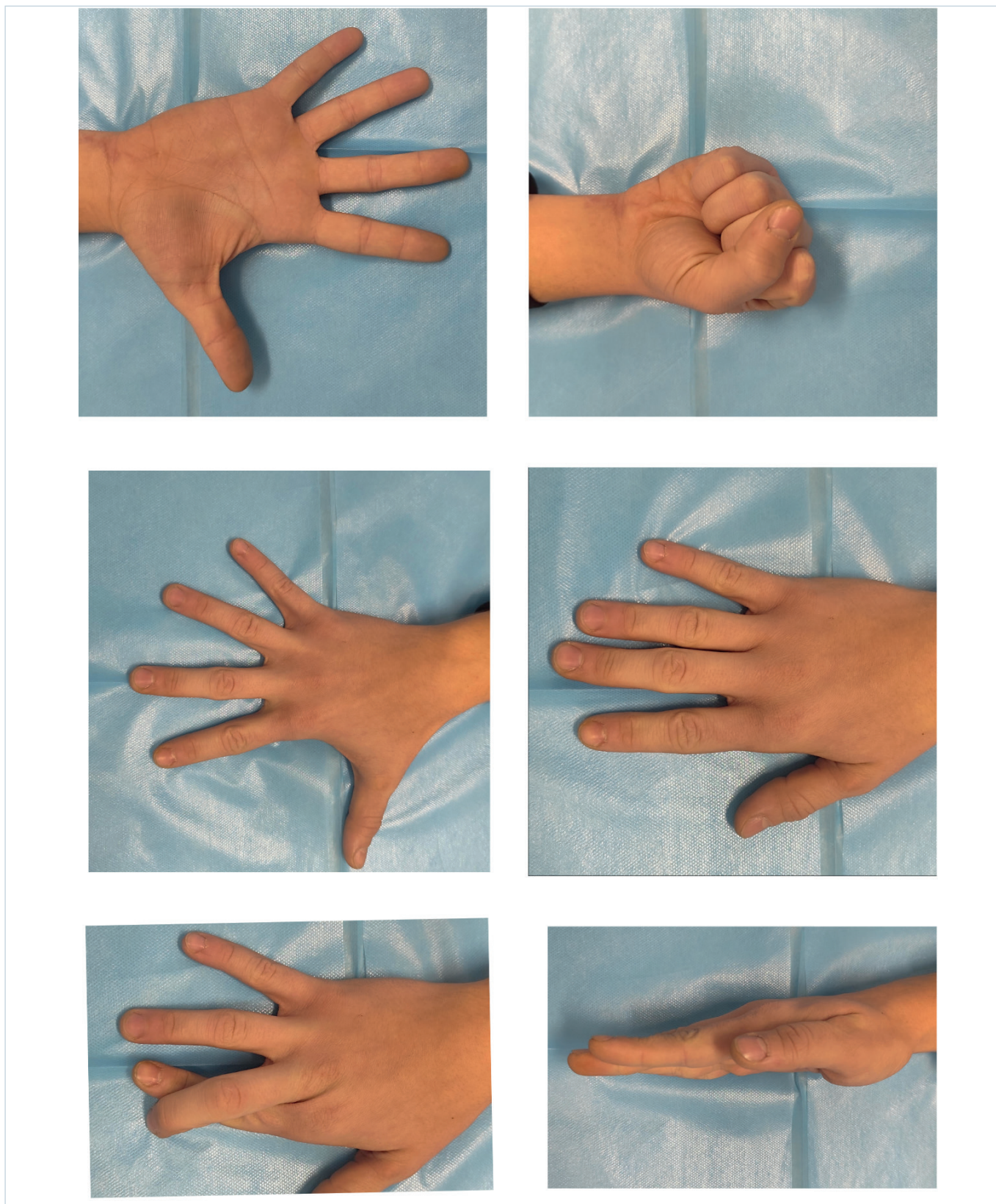


Figure 6. Six months follow-up: no motor impairment, normotrophic scar.

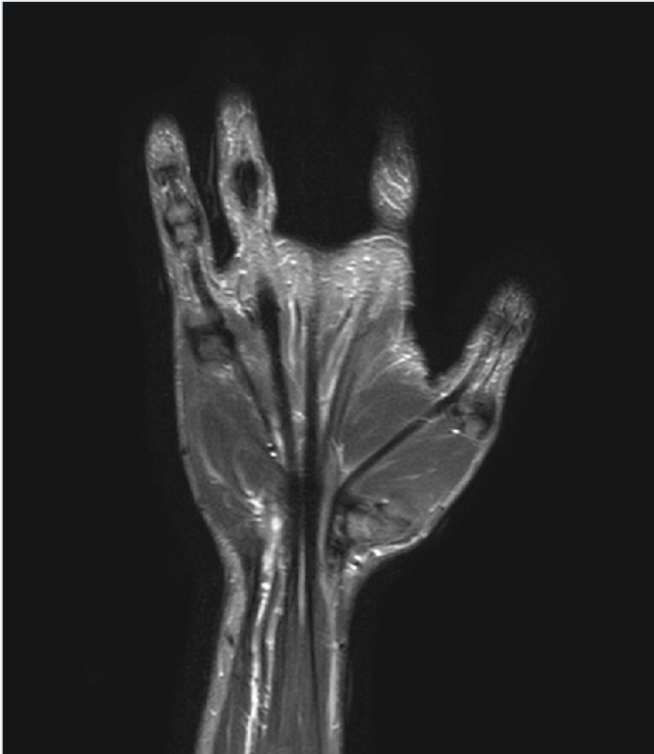

Figure 7. Contrast-enhanced magnetic resonance image after six months of surgery: no signs of local recurrence.

Discussion

Schwannomas are the most common tumors of peripheral nerves; they are benign lesions originating from Schwann cells along the course of the nerve; usually found as a solitary lesion but rarely they could have a multinodular presentation related or not to neurofibromatosis type 2. Malignant transformation is rare ¹⁶.

First described by Verocay in 1908 ¹ as "neurinoma", they account approximately 5% of all soft-tissue tumors; they most commonly occur on the head and neck, followed by the trunk and then the upper (19%) and lower limbs (17.5%); the volar surface of the limb is an anatomical space where we frequently find schwannomas because of the high concentration of nerve fibers ⁵; they occur in patient 30 to 60 years of age, without difference in gender or ethnicity ^{6,7}.

Antoni in 1920 ⁸ distinguished two tissue type based on cell morphology and spatial arrangement defined as Antoni A (hypercellular area) and Antoni B (lower cell density area) histologic patterns.

In 1932, Nageotta ⁹ proposed that encapsulated nerve sheath tumors arose from Schwann cells and coined the term "schwannoma".

Multinodular schwannoma is a rare variant of conventional

schwannoma that accounts for only 5% of all schwannomas; they both consist exclusively of Schwann cells and they have same benign pathological behavior. Each of the nodules of multiple schwannomas typically consists of cellular predominancy of Antoni A-type tissue with lack of Antoni B areas and a strong positivity with immunohistochemical markers like S-100 protein indistinguishable from that seen in a typical, solitary schwannoma. In contrast, neurofibromas consist of a combination of disorganized arrays of Schwann cells, fibroblasts, and axons, with a prominent myxoid matrix (Antoni B areas) associated with weakly S-100 protein positive reaction. The multinodular pattern has various peculiar forms of presentation: discontinuous, as a "rosary chain"; continuous, as a "string of beads"; confluent, resembling "puzzle tiles" or a "profiteroles cake" ¹⁰.

Schwannomas are usually well capsulated masses that arise from Schwann cells of a single nerve fiber and displace nerve fascicles as they grow. However, neurofibroma occur as mass spreading between nerve fascicles circumferentially involving them ^{11,15}.

Differential diagnosis between schwannoma and neurofibroma is clinically relevant, because the second one may undergo malignant degeneration.

Multiple schwannomas usually appear as multinodular subcutaneous masses characterized by slow growth, often asymptomatic; Tinel's sign and neurological impairment are not always present. The lack of specific clinical signs increases the risk of improper or delayed diagnosis.

In the treatment of schwannoma a correct diagnosis is essential and, for this purpose, magnetic resonance is considered the best preoperative imaging study to assess lesion location and origin, tumor composition that may predict aggressiveness or malignancy and tumor extent for both staging and treatment planning ⁴.

When benign nerve sheath tumors are suspected, transcutaneous biopsy is not indicated because of an unacceptably high risk for neurological deficit given the intimate relationship between functioning nerve fascicles and tumor tissue ¹⁴. When intraoperative diagnosis is uncertain despite adequate magnified exposure of the lesion, an incisional intraneural biopsy can be performed with closure of the wound pending histological confirmation ¹⁷.

The proper treatment is surgical exploration under magnification; schwannomas usually may be shelled out without interrupting nerve fasciculi; microsurgical skills are fundamental to have an appropriate and delicate manipulation of the tissues and to master all the knowledge to perform neuroorrhaphy or nerve graft when nerve resection is required. The prognosis for patients with multiple schwannomas is favourable. Early and complete surgical removal is a positive prognostic factor to reduce the risk of recurrence.

Conclusions

Schwannomas are the most common benign tumor arising from sheath of peripheral nerve; medical history and clinical examination must be meticulous to avoid improper or delayed diagnosis; upper limb and ulnar nerve localisation is rare and only very few cases are reported in literature; imaging assessment with magnetic resonance allow us to know the tumor location and which nerve is involved for both staging and treatment planning.

The prognosis for patients with schwannoma is excellent following simple excision which is the treatment of choice. Microsurgical skills are mandatory to achieve complete tumor removal without neurological loss and nerve reconstruction if required.

References

- 1 Verocay J. Zur Kenntnis der "neurofibrome." Ziegler Beitrage zur Path Anat 1910;48:1-69
- 2 Raj C, Chantelot C, Saab M. Predictive factors of postoperative deficit and functional outcome after surgery for upper limb schwannomas: Retrospective study of 21 patients. *Hand Surg Rehabil.* 2020 May;39(3):229-234. <https://doi.org/10.1016/j.hansur.2020.02.001>. Epub 2020 Feb 27. PMID: 32061856.
- 3 Tang CY, Fung B, Fok M, Zhu J. Schwannoma in the upper limbs. *Biomed Res Int.* 2013;2013:167196. <https://doi.org/10.1155/2013/167196>. Epub 2013 Sep 4. PMID: 24093090; PMCID: PMC3777180.
- 4 Mann FA, Murphy WA, Totty WG, Manaster BJ. Magnetic resonance imaging of peripheral nerve sheath tumors. Assessment by numerical visual fuzzy cluster analysis. *Invest Radiol.* 1990 Nov;25(11):1238-45. <https://doi.org/10.1097/00004424-199011000-00017>. PMID: 2123835.
- 5 Adani R, Baccarani A, Guidi E, Tarallo L. Schwannomas of the upper extremity: diagnosis and treatment. *Chir Organi Mov.* 2008 Sep;92(2):85-8. <https://doi.org/10.1007/s12306-008-0049-0>. Epub 2008 Jul 8. PMID: 18612585.
- 6 Perteau M, Filip A, Huzum B, Lunca S, Carp C, Mitrea M, Toader P, Luca S, Moraru DC, Poroch V, Veliceasa B. Schwannoma of the Upper Limb: Retrospective Study of a Rare Tumor with Uncommon Locations. *Diagnostics (Basel).* 2022 May 26;12(6):1319. <https://doi.org/10.3390/diagnostics12061319>. PMID: 35741129; PMCID: PMC9222006.
- 7 Galbiatti JA, Milhomens GRDS, Bertozzo LG, Escames L, Milhomens Neto PA, Galbiatti MGP. Retrospective Analysis of 20 Patients Affected by Schwannomas in the Upper and Lower Limbs. *Rev Bras Ortop (Sao Paulo).* 2020 Oct;55(5):629-636. <https://doi.org/10.1055/s-0040-1702962>. Epub 2020 Apr 6. PMID: 33093729; PMCID: PMC7575399.
- 8 Antoni NRE. *Über guckenmarkstumoren und Neurofibrome; Studien zur pathologischen Anatomie und Embryogenese; mit einem plinischen Amrang.* Munich: J.F. Bergmann, 1920.
- 9 Nageotta J. Sheaths of the peripheral nerves. In: Penfield W, ed. *Cytology and cellular pathology of the nervous system.* Vol. 1. New York: P.B. Hoeber, 1932:191-240
- 10 Sturdà C, Pennisi G, D'Alessandris QG, Mattogno P, Fernandez E, Granata G, Gessi M, Lauretti L. Multinodular plexiform tumors of major peripheral nerves: A practical overview. *J Clin Neurosci.* 2021 Nov;93:106-111. <https://doi.org/10.1016/j.jocn.2021.09.022>. Epub 2021 Sep 17. PMID: 34656232.
- 11 Vigasio A, Marcoccio I, Prestini G, Mattiuzzo V, Patelli A. 32 casi di Schwannoma solitario benigno dell'arto superiore: aspetti diagnostici e terapeutici. *Riv Chir Mano - Vol. 43 (1)2006*
- 12 Adani R, Tarallo L, Mugnai R, Colopi S. Schwannomas of the upper extremity: analysis of 34 cases. *Acta Neurochir (Wien).* 2014 Dec;156(12):2325-30. <https://doi.org/10.1007/s00701-014-2218-2>. Epub 2014 Sep 17. PMID: 25223747.
- 13 Ozdemir O, Ozsoy MH, Kurt C, Coskunol E, Calli I. Schwannomas of the hand and wrist: long-term results and review of the literature. *J Orthop Surg (Hong Kong).* 2005 Dec;13(3):267-72. <https://doi.org/10.1177/230949900501300309>. Erratum in: *J Orthop Surg (Hong Kong).* 2006 Aug;14(2):following 229. PMID: 16365490.
- 14 Perez-Roman RJ, Shelby Burks S, Debs L, Cajigas I, Levi AD. The Risk of Peripheral Nerve Tumor Biopsy in Suspected Benign Etiologies. *Neurosurgery.* 2020 Mar 1;86(3):E326-E332. <https://doi.org/10.1093/neuros/nyz549>. PMID: 31927583.
- 15 Ferner RE, O'Doherty MJ. Neurofibroma and schwannoma. *Curr Opin Neurol.* 2002 Dec;15(6):679-84. <https://doi.org/10.1097/01.wco.0000044763.39452.aa>. PMID: 12447105.
- 16 Ferner RE. Neurofibromatosis 1 and neurofibromatosis 2: a twenty first century perspective. *Lancet Neurol.* 2007 Apr;6(4):340-51. [https://doi.org/10.1016/S1474-4422\(07\)70075-3](https://doi.org/10.1016/S1474-4422(07)70075-3). PMID: 17362838.
- 17 Strike SA, Puhaindran ME. Nerve Tumors of the Upper Extremity. *Clin Plast Surg.* 2019 Jul;46(3):347-350. <https://doi.org/10.1016/j.cps.2019.02.008>. PMID: 31103079.