



Myopericytoma at the finger: case-report and literary review

Miopericitoma del dito: caso clinico e revisione della letteratura

Margherita Menozzi, Andrea Leti Acciario, Stefania Vanni, Roberto Adani

Master di II livello in Chirurgia della Mano e Microchirurgia, Unimore e S.C. di Chirurgia della Mano e Microchirurgia, AOU Policlinico of Modena

Summary

Purpose. A case of digital myopericytoma is described and a literary review is reported to document the clinical and histopathological findings of the tumor at the hand, enhancing its diagnosis and comprehension.

Materials and methods. Myopericytoma was diagnosed and surgically excised from the pulpar aspect of the right thumb in a 54-years old male, without recurrence and with complete functional recovery at the follow-up. Fifteen cases of digital myopericytoma were reported in 8 papers.

Discussion. Myopericytoma may be overlooked on differential diagnosis and presents potential for mimicry and malignancy. Excisional biopsy with complete surgical resection was the treatment of choice. Definitive diagnosis was achieved due to histological examination. Recurrences were rarely described and malignancy was exceptional. The literary review of the management and outcomes of digital cases was presented.

Conclusions. The peculiar histopathological and immunohistochemical examination is essential in diagnosis as well as comprehension of the neoplasm features in clinical examination.

Key words: myopericytoma, hand tumor, thumb tumor, thumb myopericytoma

Riassunto

Scopo. Descrivere un caso di miopericitoma digitale ed eseguire una revisione della letteratura, per descriverne le caratteristiche istopatologiche e per migliorarne la diagnosi e la conoscenza.

Materiali e metodi. A un paziente maschio di 54 anni è stato diagnosticato e successivamente asportato chirurgicamente un miopericitoma dal polpastrello del pollice, non si sono verificate recidive e c'è stato un completo recupero funzionale. In letteratura sono stati descritti 15 casi di miopericitomi in 8 pubblicazioni.

Discussione. Il miopericitoma può essere misconosciuto alla diagnosi differenziale e possiede un rischio di trasformazione maligna. Il trattamento di elezione è la biopsia escissionale con completa asportazione della lesione. La diagnosi definitiva viene fatta con l'esame istologico. Le recidive sono state descritte infrequentemente e la trasformazione maligna è una rarità. Viene presentata la revisione della letteratura in merito al trattamento e ai risultati nelle localizzazioni digitali.

Conclusioni. L'esame istologico e immunoistochimico sono di fondamentale importanza per la diagnosi, così come la conoscenza delle caratteristiche del tumore all'esame clinico.

Parole chiave: miopericitoma, tumore della mano, tumore del pollice, miopericitoma del pollice

Corrispondenza

Margherita Menozzi

E-mail: margherita.menozzi@gmail.com

Conflitto di interessi

Gli Autori dichiarano di non avere alcun conflitto di interesse con l'argomento trattato nell'articolo.

Come citare questo articolo: Menozzi M, Leti Acciario A, Vanni S, et al. Myopericytoma at the finger: case-report and literary review. Rivista Italiana di Chirurgia della Mano 2022;59:41-44. <https://doi.org/10.53239/2784-9651-2022-5>

© Copyright by Pacini Editore Srl



OPEN ACCESS

L'articolo è OPEN ACCESS e divulgato sulla base della licenza CC BY-NC-ND (Creative Commons Attribuzione - Non commerciale - Non opere derivate 4.0 Internazionale). L'articolo può essere usato indicando la menzione di paternità adeguata e la licenza; solo a scopi non commerciali; solo in originale. Per ulteriori informazioni: <https://creativecommons.org/licenses/by-nc-nd/4.0/deed.it>

Introduction

Pericytes are perivascular cells adjacent to capillaries in a variety of tissues, continuous with vascular muscle cells¹. These pluripotent cells may differentiate into smooth muscle cells, adipocytes or osteoblasts. Neoplasms arising by this line of differentiation has been described as Hemangiopericytomas, but exhibited a spectrum of growth patterns which overlap within a series of hemangiopericytoma-like (HPC-like) vascular pattern including from fibrous to myoid tumors².

Myopericytoma is a delineated entity with both HPC-like vascular architectural pattern and features of perivascular myoid (myopericytic) differentiation, presenting an overlapping morphologic features from myofibroma to angioleiomyoma². Because of this range of histological growth patterns, myopericytoma may be frequently misdiagnosed as other tumors or sarcoma³.

Despite the benignity of the neoplasm, malignant variant is documented with histopathologically increased proliferative and mitotic activity, cellular atypia and areas of necrosis^{2,4,5}. Myopericytoma occurs in dermal and superficial soft tissues of adult. The lower extremities are more commonly involved than the upper extremities, and multiple primary locations are occasionally described even at the fingers^{6,7}.

Given the potential for mimicry, the rarity and the morphopathological complexity of this rare tumor of the soft tissue, the myopericytoma poses relevant challenges for surgeon and anatomopathologist in order to correctly frame the lesion on a differential diagnosis. The current case-report and review in finger location of the tumor may provide a useful management and identification of the digital lesion.

Case report

A 54-year-old caucasian male, with no relevant medical history and no referred trauma, presented to our Hand Surgery Center with a lesion that had appeared 4 months earlier on the pulp of the thumb of his right-dominant hand. The tumefaction extended from the pulp to the volar aspect of the flexion crease of the interphalangeal joint (IPJ) of the thumb, showing a well-defined nodule with a hyperkeratotic and almost ulcerative central lesion (Fig. 1). The lesion was referred as a slow-growing mass, was solid and painfulness, with no erythematous or swelling, and movable on the underlying plane. The finger was neurovascularly intact. The range of motion at the IPJ was reduced in flexion (from -15° of hyperextension to 65°) due to the pain induced by the ulceration and the mechanical limitation of the mass at the crease. Ultrasound documented the well-circumscribed solid mass and radiographic examination showed no features correlated with the lesion.

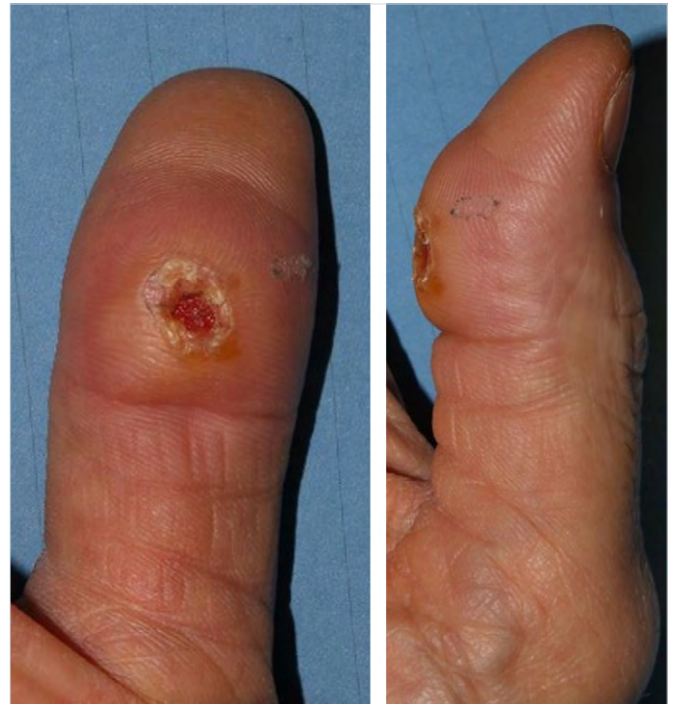

Figure 1. Clinical aspect of the neof ormation presenting the nodule with hyperkeratotic and ulcerative central lesion at the thumb.

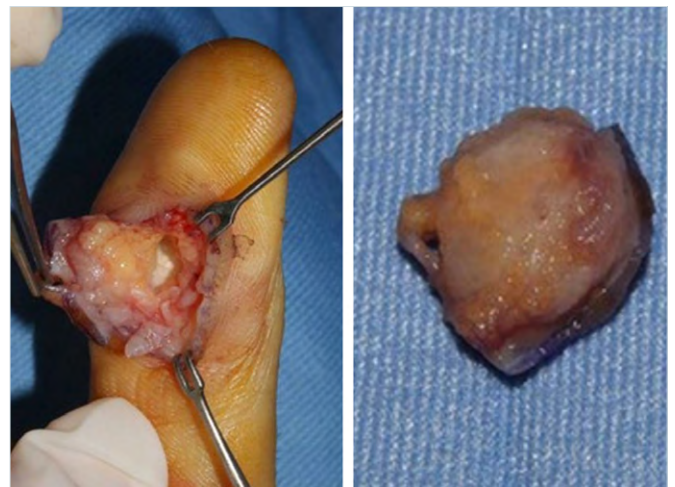


Figure 2. Intra-operative features of the complete excision with overlying skin of the unencapsulated lesion, involving dermal and superficial soft tissues at the proximal site of the pulp.

The patient underwent total removal of neof ormation, in digital block anaesthesia, with section of a lozenge portion of the overlying skin. The mass appeared unencapsulated and once the clamping point was found, the piece was completely removed (Fig. 2). A Local advancement flap closure was

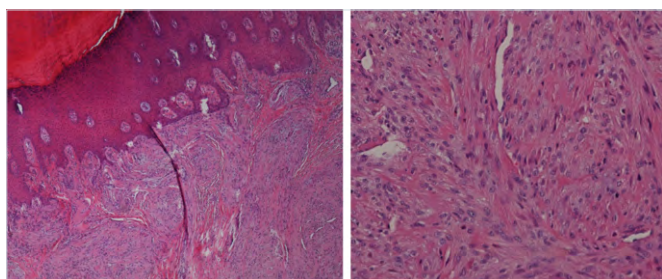


Figure 3. Histologic features of the tumor showing ovoid spindle cells with elongated nuclei and eosinophilic cytoplasm, arranged in a concentric fashion around blood vessels.

harvested according to Dufourmentel design⁸. The excisional biopsy was sent to histological examination.

Histologically, the tumor was composed of ovoid spindle cells with elongated nuclei and eosinophilic cytoplasm, arranged around numerous thin or dilated blood vessels, in a concentric fashion (Fig. 3). Nuclear atypia was absent and very rare mitotic figures were visible. By immunohistochemistry, the lesion showed positivity for smooth muscle actin stain and focal positivity for desmin, whereas cytokeratins, EMA, S-100 protein and CD34 were completely negative. A histological diagnosis of myopericytoma was rendered.

At the 14 months follow-up the patient had no evidence of local recurrence on physical examination, all daily and work-related activities were allowed. Fibrosis in the site of the scar and local flap was detected with some residual lack of sensibility referred by patient. The pulp was intact with normal sensation at the Semmes-Weinstein monofilament test scoring, as well as normal strength in pinching. The

range of motion at the IPJ was complete and symmetric in active and passive flexion and extension with the contra-lateral thumb.

The literary review was performed recurring to the PubMed and Medline Plus databases and Researchgate, searching: myopericytoma, hand, digital, finger, and miopericitoma (to include also different languages from English).

Discussion

Myopericytoma represents a rare perivascular myoid tumor arising predominantly in dermal and subcutaneous tissues of the extremities of adults⁹.

The literature review showed isolated case reports or small case-series of myopericytoma at the hand. In only eight papers (two in Spanish) a digital myopericytoma was described^{2,3,5,7,10,11}. Fewer than 30 cases at the hand have been recorded and in 14 of these patients (16 fingers) myopericytoma was at the finger level. One patient had a multiple localization at three fingers of the same hand (Tab. I).

Digital presentation was heterogeneous according to history of trauma, pain, erythema, and bone erosion. More common features were the slowly but steady enlargement over time, the pulpar location and the hyperkeratotic aspect. In cases with prevalent vascular pattern a bloody discharge was described by Stout et al.^{11,12}. At the hand nerve compression may occur^{13,14}.

Instrumental examinations were not always indicated because the sensitivity in diagnosis and pre-operative planning was poor, even in ultrasound and magnetic resonance.

Most cases behaved in a benign fashion. Few reports of local recurrences were described despite the high frequency of incomplete excision. Surgically adequate and clear resection

Table I. Literary review: 16 digital locations in 14 patients described in eight papers of single case-report or case-series.

	Thumb	Index	Middle	Ring	Little	Unknown	Clinical peculiarity
Stout et al.		1		1			Bloody discharge in vascular pattern
Mahapatra et al.				1			Painful, digital artery
Gracia-Jimenez et al.					1		Painful, pulpar
Boix-Vilanova et al.			1				Previous injury, hyperkeratotic, pulpar
Morzycki et al.		1					Painful, erythema, phalanx erosion, pulpar
Dray et al.	1					2	Unknown
Mentzel et al.	1					3	Unknown
Sadahira et al.			1	1	1		Ungueal, glomus-like
			Same patient				

of the mass was described hard to attain because of indefinite margins^{2,6}. The surgical approach included the complete excision of neof ormation in a local anesthesia and in outpatient setting¹⁵⁻²⁰. There is a trend toward tissue conservation in even the more expanded lesion. Metastases have been described exceptionally rare, always in presence of atypical malignant pattern in histopathology with following severe prognosis.

According to the several biopsy modalities, the excisional one was selected to provide early digital function recovery, despite the potentially greater risk of tumor spread and complication. It also has been shown to be superior in the diagnosis, and the exclusion of malignant variant was a relevant matter according to the severe outcomes described.

Because of the range of morphologic features, myopericytoma often needed to be overlooked on differential diagnosis^{6,21,22}. Absolute diagnosis depended on histological confirmation of the peculiar features. Myopericytoma has been described as characterized by the presence of numerous thin-walled blood vessels concentrically surrounded by ovoid, plump, spindle, and round myoid tumor cell. The immunohistochemical examination is essential because of the positive alpha-actin and negative desmin pattern^{2,9}.

References

- Zimmerman K. Der feinere bau der blutkapillaren. *A Anat Entwicklungsgesch* 1923;68:29-109.
- Mentzel T, Dei Tos AP, Sapi Z, et al. Myopericytoma of skin and soft tissues: clinicopathologic and immunohistochemical study of 54 cases. *Am J Surg Pathol* 2006;30:104-113. <https://doi.org/10.1097/01.pas.0000178091.54147.b1>
- Dray MS, McCarthy SW, Palmer AA, et al. Myopericytoma: a unifying term for a spectrum of tumours that show overlapping features with myofibroma. A review of 14 cases. *J Clin Pathol* 2006;59:67-73. <https://doi.org/10.1136/jcp.2005.028704>
- McMenamin ME, Fletcher CD. Malignant myopericytoma: expanding the spectrum of tumours with myopericytic differentiation. *Histopathology* 2002;41:450-460. <https://doi.org/10.1046/j.1365-2559.2002.01537.x>
- Boix-Vilanova J, Del Pozo Hernando LJ, Rodrigo Lara H, et al. Distal digital myopericytoma: a dermoscopic case study. *Actas Dermosifiliogr (Engl Ed)* 2020;111:338-341. <https://doi.org/10.1016/j.jad.2018.09.015>
- Morzycski A, Joukhadar N, Murphy A, et al. Digital myopericytoma: a case report and systematic literature review. *J Hand Microsurg* 2017;9:32-36. <https://doi.org/10.1055/s-0037-1601397>
- Sadahira C, Yoneda K, Moriue T, et al. Periungual myopericytoma. *J Am Acad Dermatol* 2006;54:1107-1108. <https://doi.org/10.1016/j.jaad.2006.01.057>
- Benanti E, De Santis G, Leti Acciaro A, et al. Soft tissue coverage of the upper limb: a flap reconstruction overview. *Ann Med Surg (Lond)* 2020;60:338-343. <https://doi.org/10.1016/j.amsu.2020.10.069>
- Provenzano D, Lo Bianco S, Belfiore M, et al. Foot soft tissue myopericytoma: Case-report and review. *Int J Surg Case Rep* 2017;41:377-382. <https://doi.org/10.1016/j.ijscr.2017.10.061>
- Garcya-Jimenez A, Peiro-Ibanez A, Trullois-Tarrago L. Miopericytoma del pulpeo del dedo: caso clinico y revision de la literatura. *Rev Iberoam Cir Mano* 2016;44:110-112.
- Mahapatra P, Dunne J, Colville RJ. Digital artery intravascular myopericytoma - a rare cause of a painful finger. *J Hand Surg Eur Vol* 2015;40:753-754. <https://doi.org/10.1177/1753193414534380>
- Stout AP, Murray MR. Hemangiopericytoma: a vascular tumor featuring Zimmermann's pericytes. *Ann Surg* 1942;116:26-33. <https://doi.org/10.1097/00000658-194207000-00004>
- Starnoni M, Colzani G, De Santis G, et al. Median nerve injury caused by screw malpositioning in percutaneous scaphoid fracture fixation. *Plast Reconstr Surg Glob Open* 2019;7:e2292. <https://doi.org/10.1097/GOX.0000000000002292>
- Leti Acciaro A, Pilla F, Faldini C, et al. The carpal tunnel syndrome in children. *Musculoskelet Surg* 2018;102:261-265. <https://doi.org/10.1007/s12306-017-0527-3>
- Leti Acciaro A, Montanari S, Venturelli M, et al. Retrospective study in clinical governance and financing system impacts of the COVID-19 pandemic in the hand surgery and microsurgery HUB center. *Musculoskelet Surg* 2021;106:291-296. <https://doi.org/10.1007/s12306-021-007-3>
- Starnoni M, Baccarani A, Pappalardo M, et al. Management of personal protective equipment in plastic surgery in the era of coronavirus disease. *Plast Reconstr Surg Glob Open* 2020;8:e2879. <https://doi.org/10.1097/GOX.0000000000002879>
- Leti Acciaro A, Lando M, Russomando A, et al. A mini-invasive tenolysis of the flexor tendons following hand fractures: case series. *Musculoskelet Surg* 2018;102:41-45. <https://doi.org/10.1007/s12306-017-0493-9>
- Battiston B, Leti Acciaro A, DeLeo A. The role of the FESSH Hand Trauma Committee in Europe. *Handchir Mikrochir Plast Chir* 2013;45:326-331. <https://doi.org/10.1055/s-0033-1361100>
- Leti Acciaro A, Pilla F, Colzani G, et al. A new sign allowing diagnosis in the pathologies of the extensor tendons of the hand. *Injury* 2018;49:1119-1125. <https://doi.org/10.1016/j.injury.2018.01.010>
- De Santis G, Palladino T, Leti Acciaro A, et al. The Telematic solutions in plastic surgery during COVID-19 pandemic. *Acta Biomed* 2020;91(3). <https://doi.org/10.23750/abm.v91i3.10291>
- Leti Acciaro A, Gabrieli R, Landi A. A rare case of acral myxoinflammatory fibroblastic sarcoma at the hand. *Musculoskelet Surg* 2010;94:53-57. <https://doi.org/10.1007/s12306-009-0053-z>
- Ichihara S, Vaiss L, Acciaro AL, et al. External bone remodeling after injectable calcium-phosphate cement in benign bone tumor: two cases in the hand. *Orthop Traumatol Surg Res* 2015;101:983-986. <https://doi.org/10.1016/j.otsr.2015.09.019>